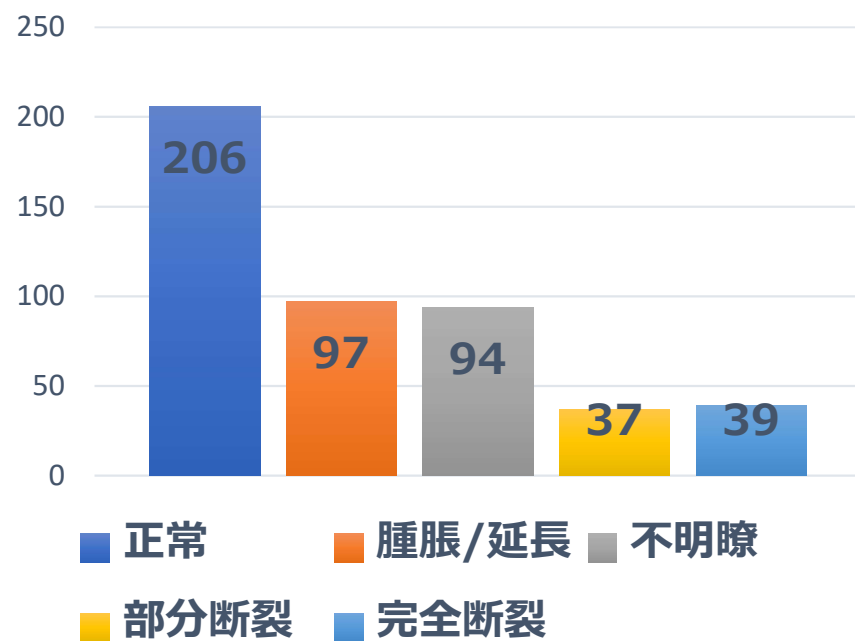
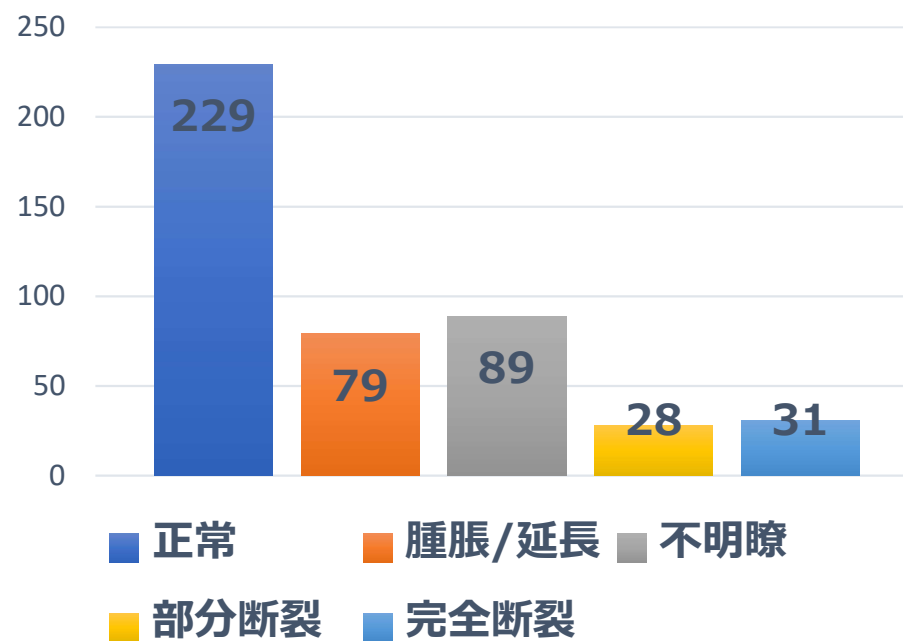


結果；前距腓韌帶

右足

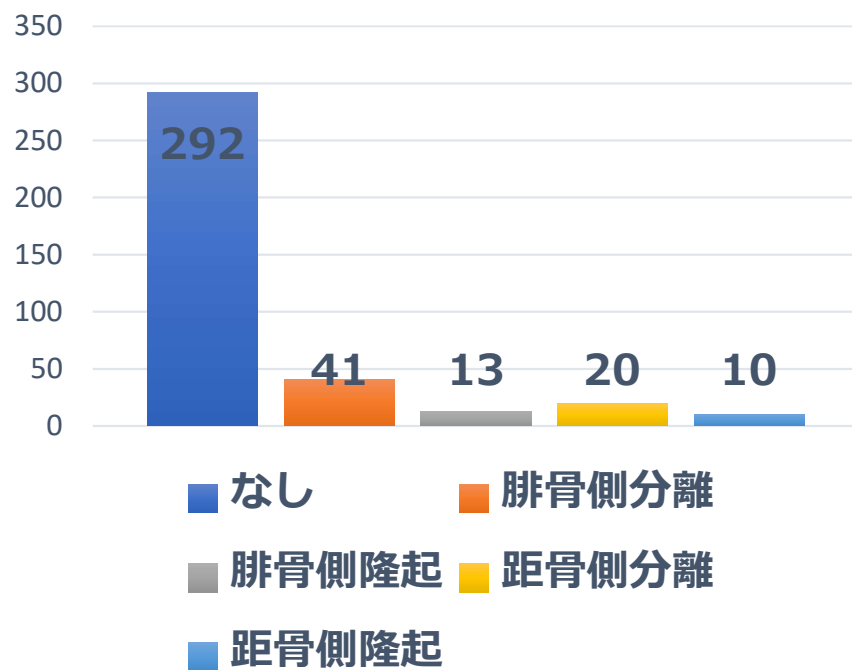


左足

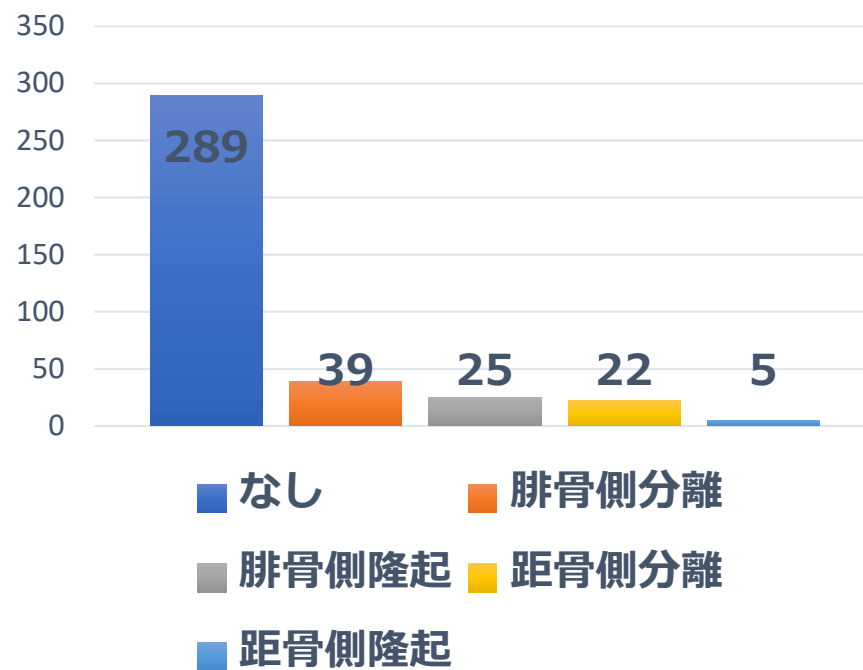


結果；陳旧性剥離骨折の有無

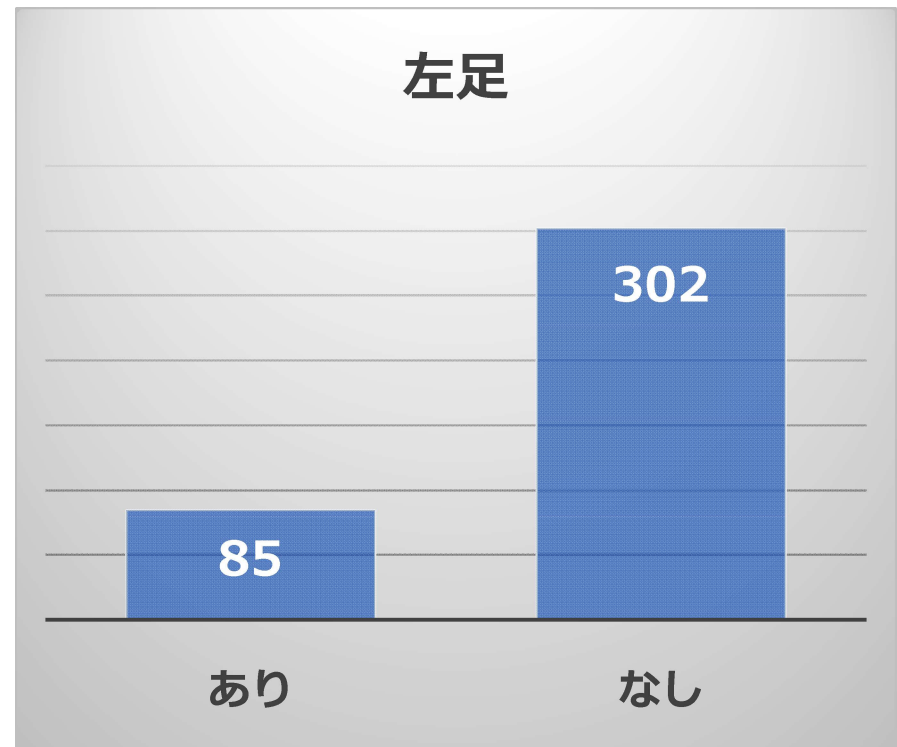
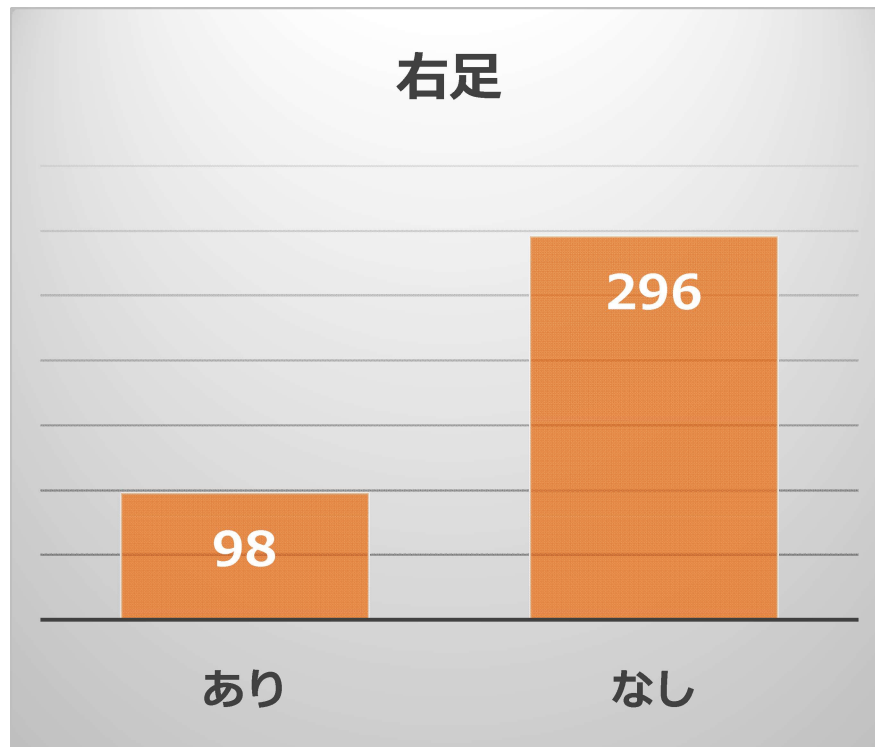
右足



左足



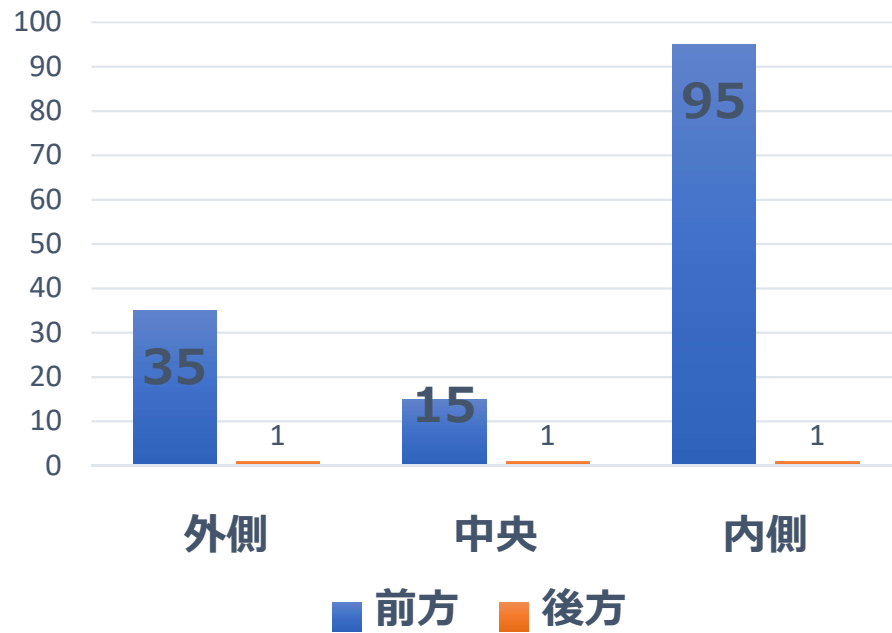
結果；足関節の動揺性



20%以上に不安定性あり

結果；距腿關節

右足



左足

